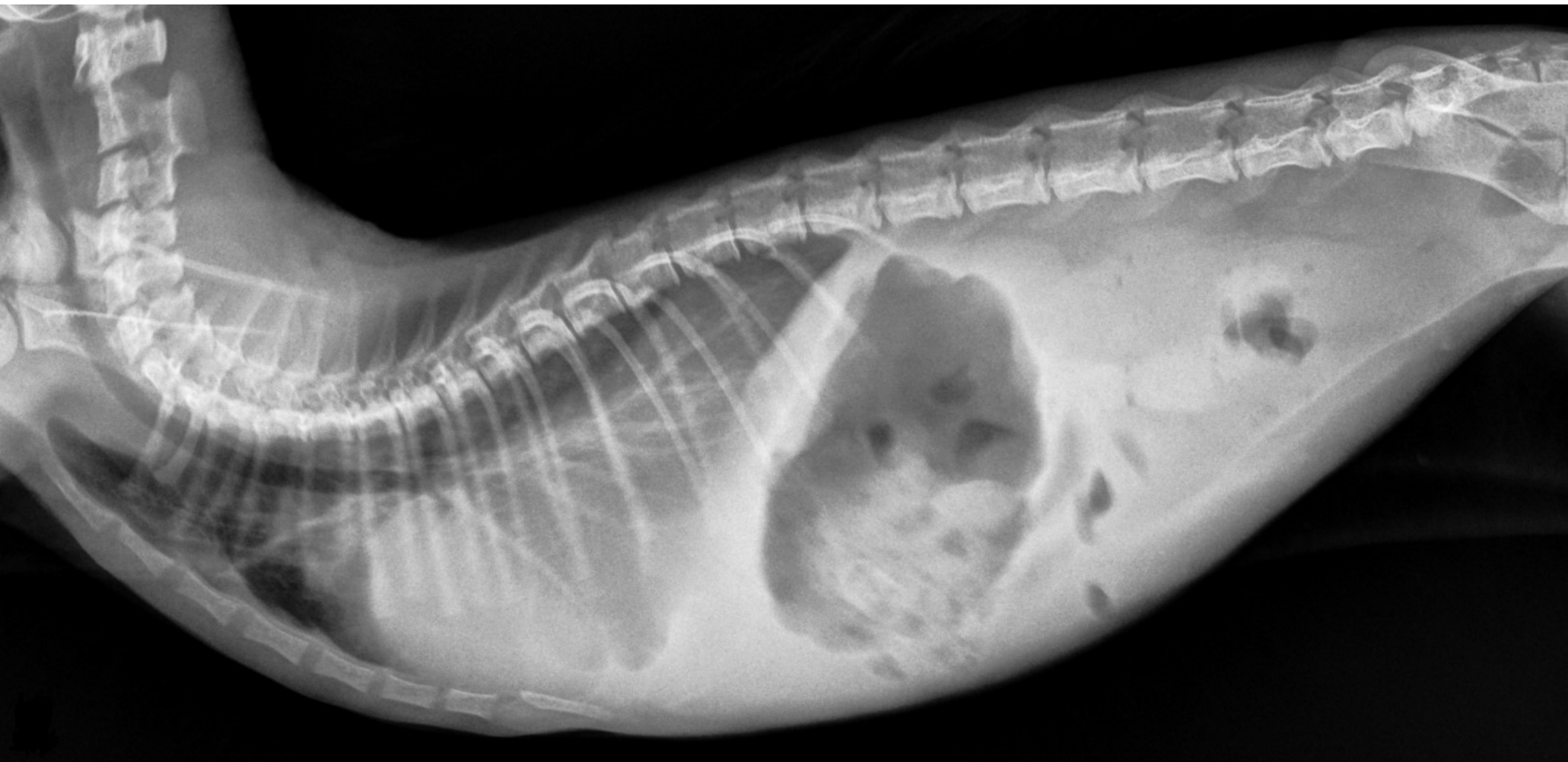
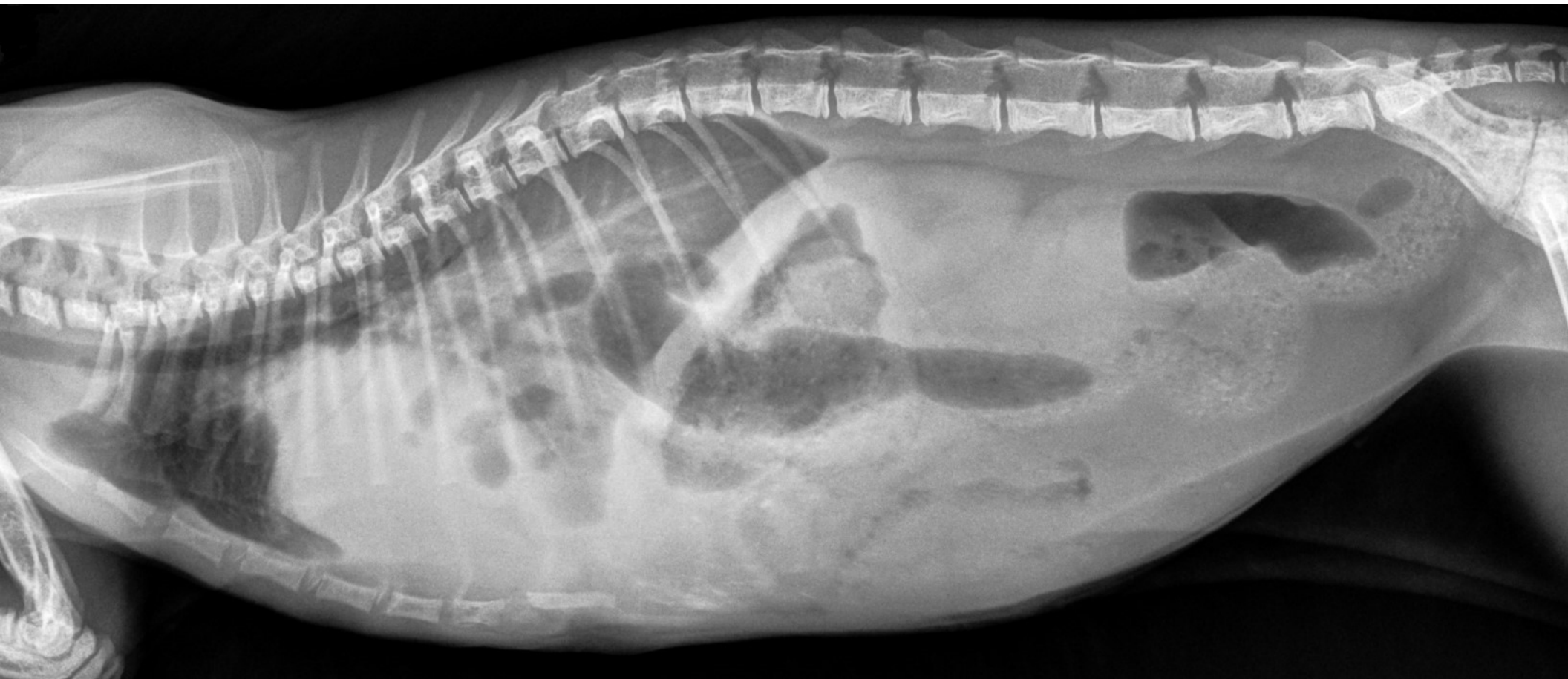
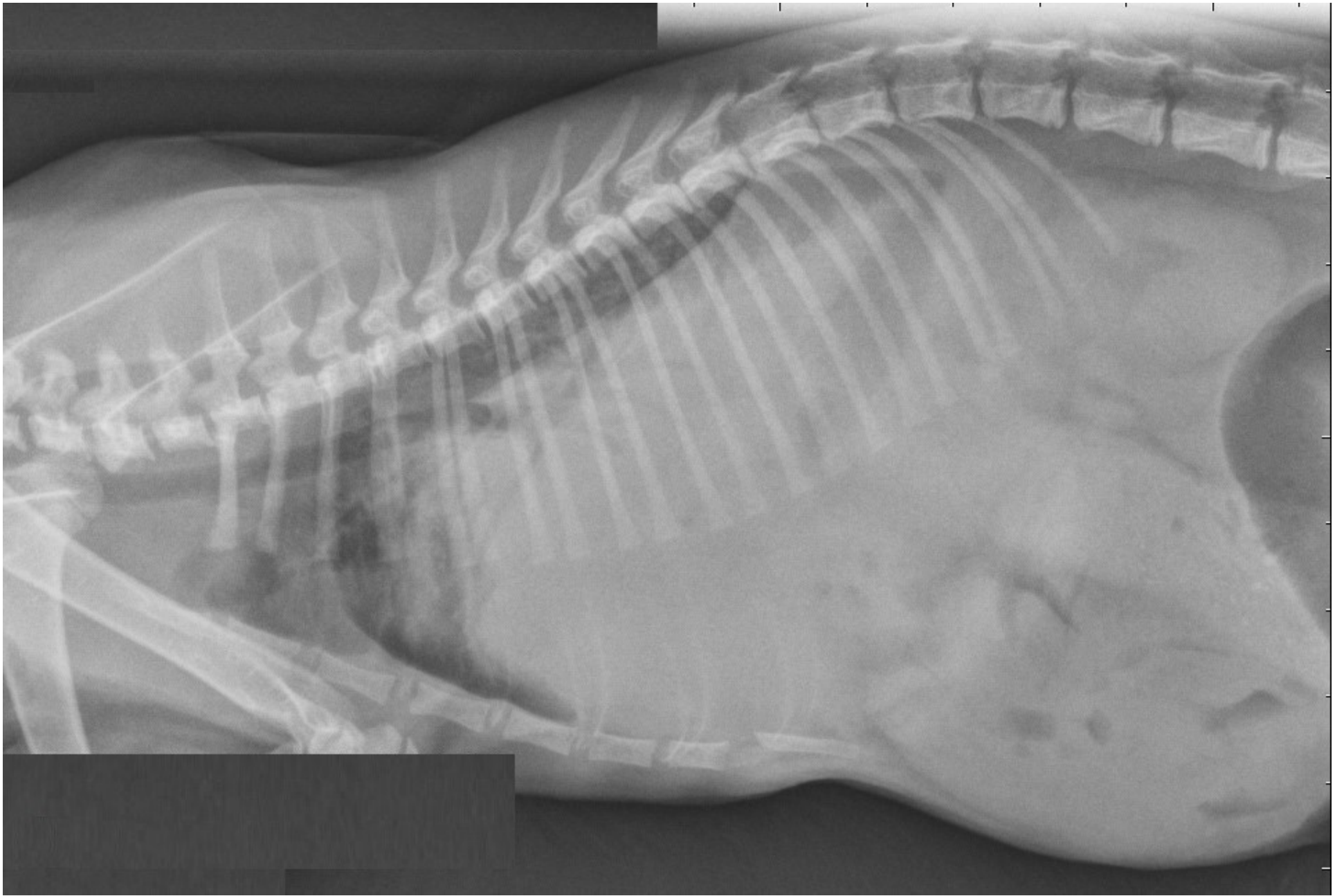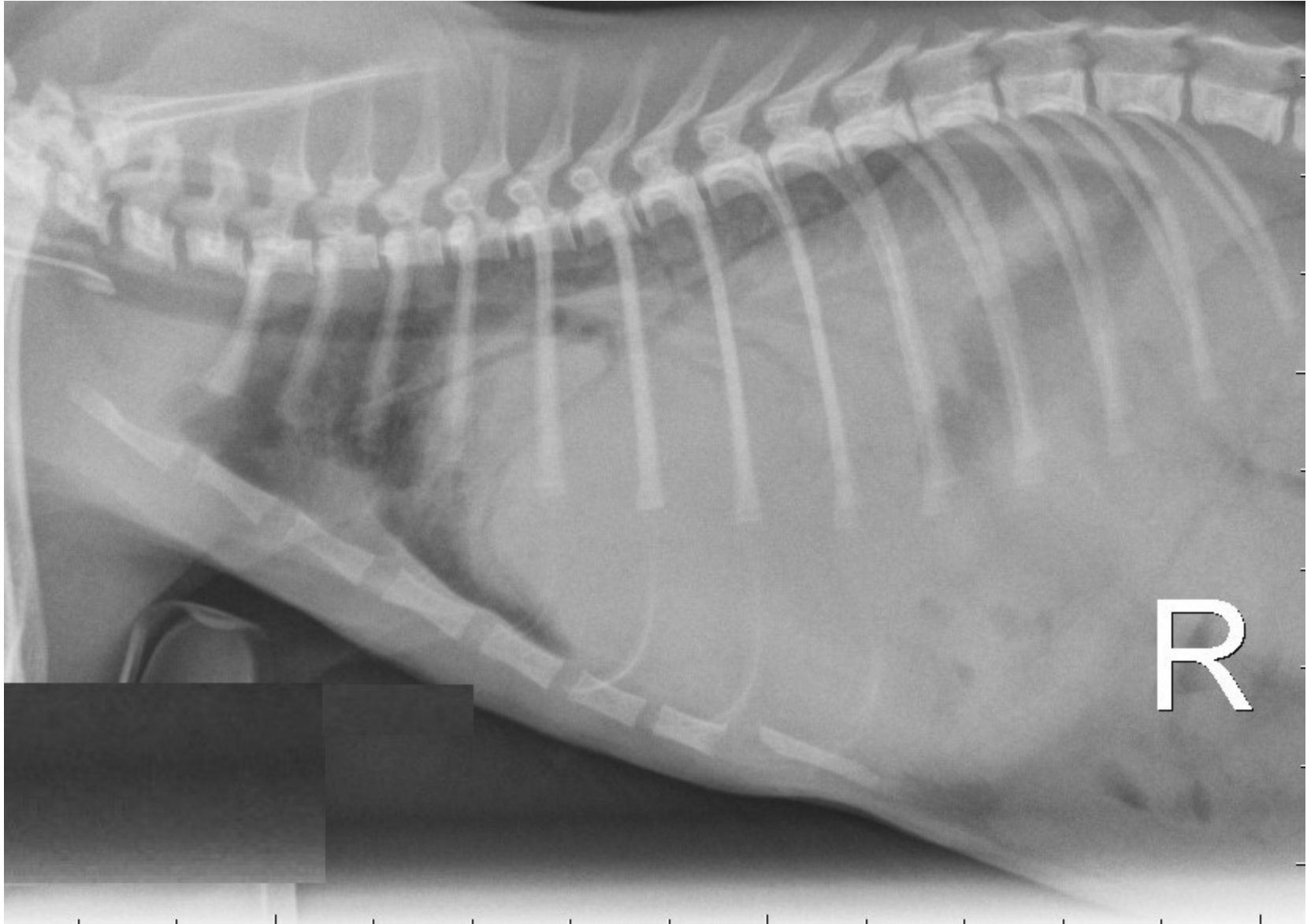
Supplementary Figure S1a. Right lateral thoracic radiographs. An alveolar pattern is observed in the caudal lobes, caudal to the heart silhouette.



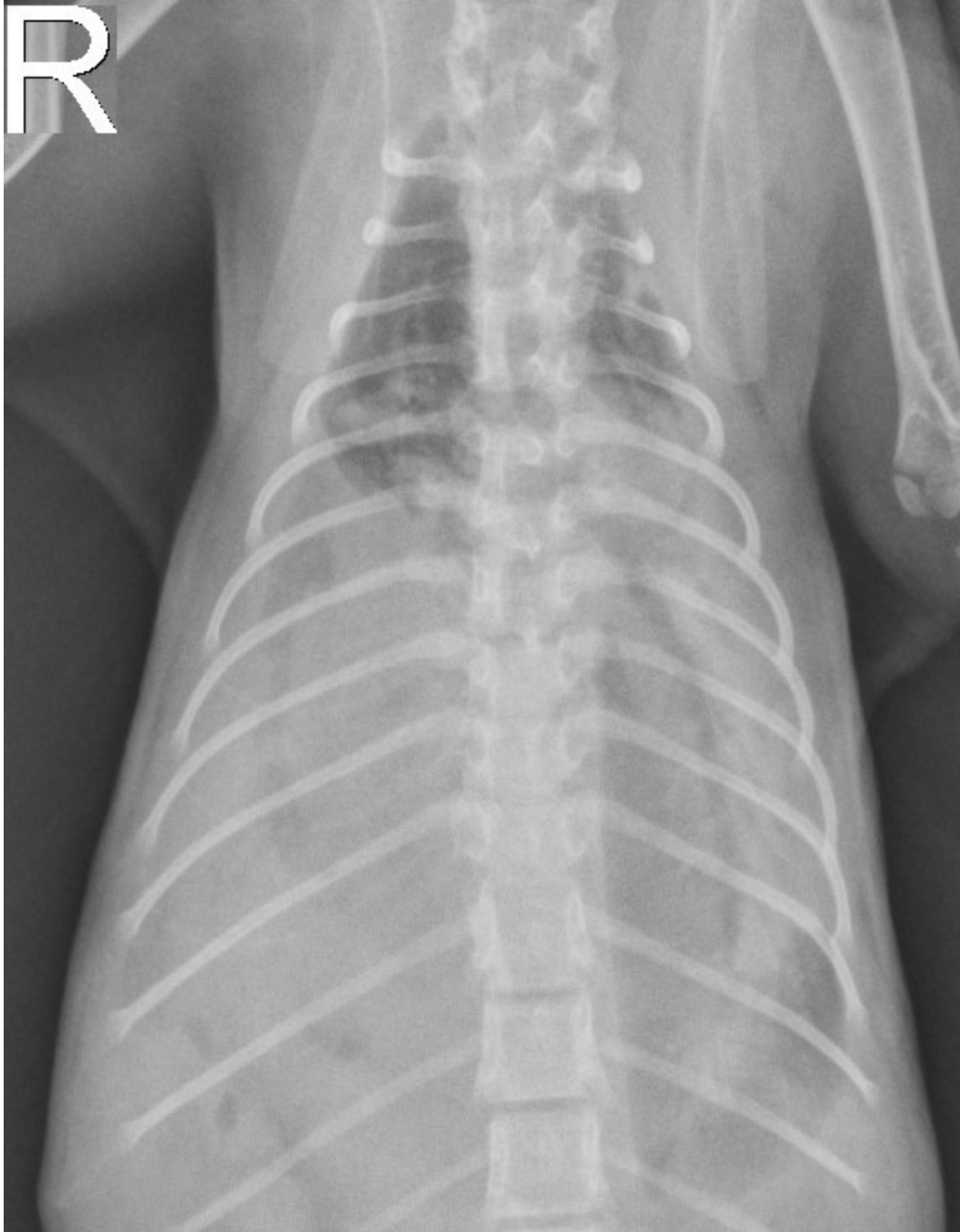Supplementary Figure S1b. follow-up right lateral thoracic radiograph. An alveolar pattern with intestinal loops full of gas is observed in the caudal lobes, caudal to the heart silhouette.



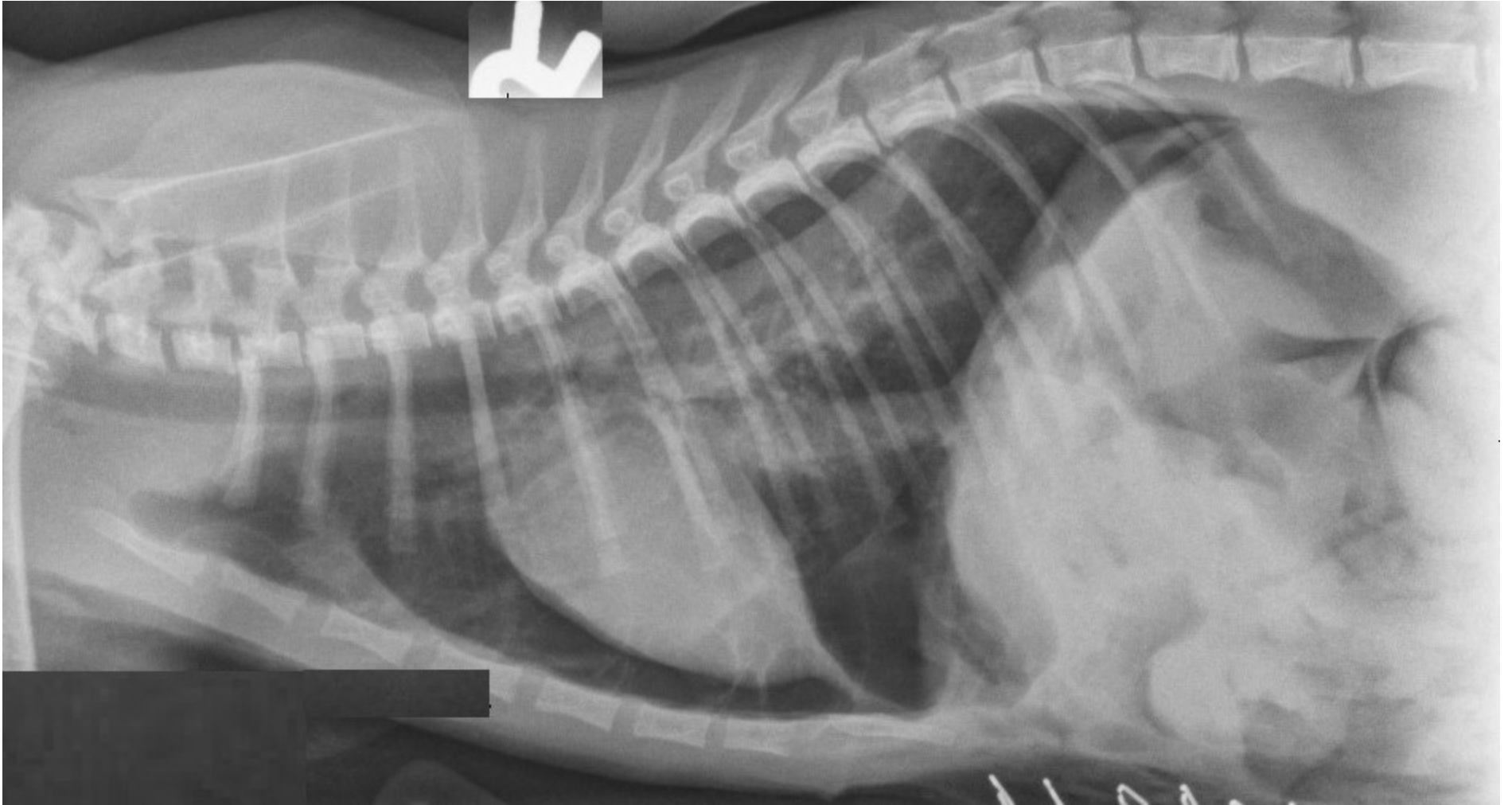Supplementary Figure S2a. left lateral thoracic radiographs prior to surgery.



Supplementary Figure S2b. right lateral thoracic radiographs prior to surgery.

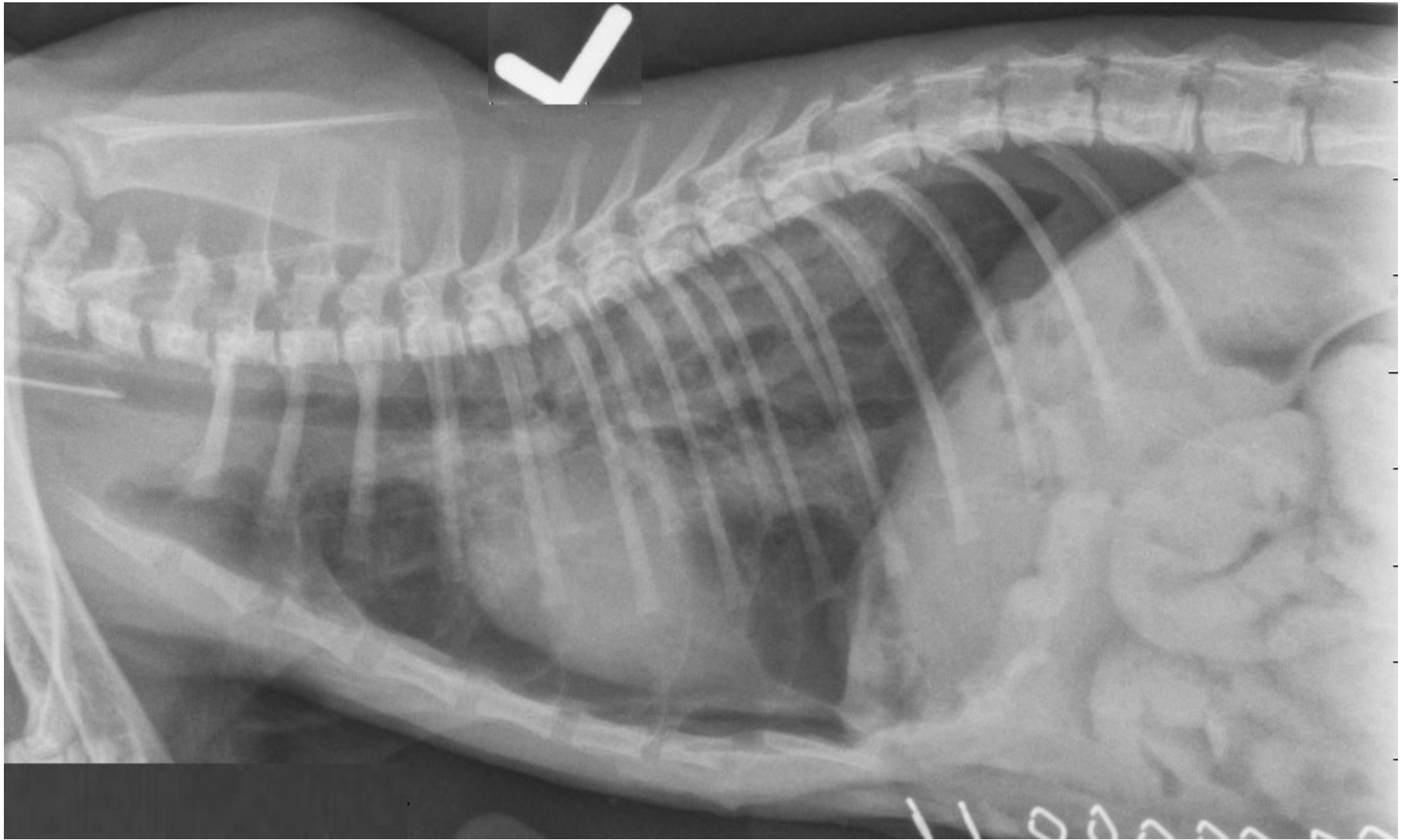


Supplementary Figure S2c. dorsoventral thoracic radiographs prior to surgery. A large, non-defined margined soft tissue opacity is present in the caudal thorax, and caudal do the remaining heart silhouette in all three radiographs.

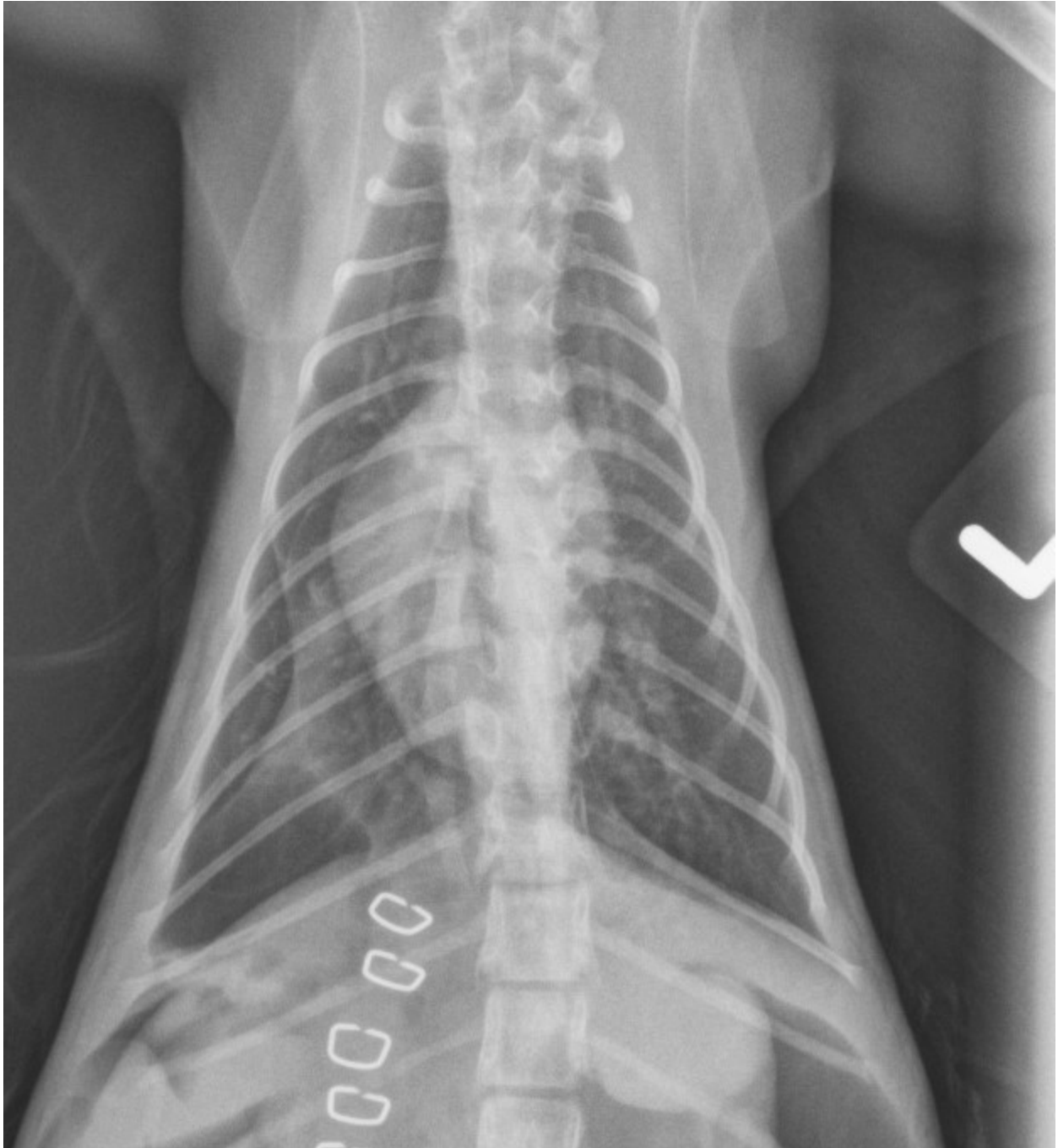


Supplementary Figure S3a. right lateral thoracic radiographs immediately after surgery.



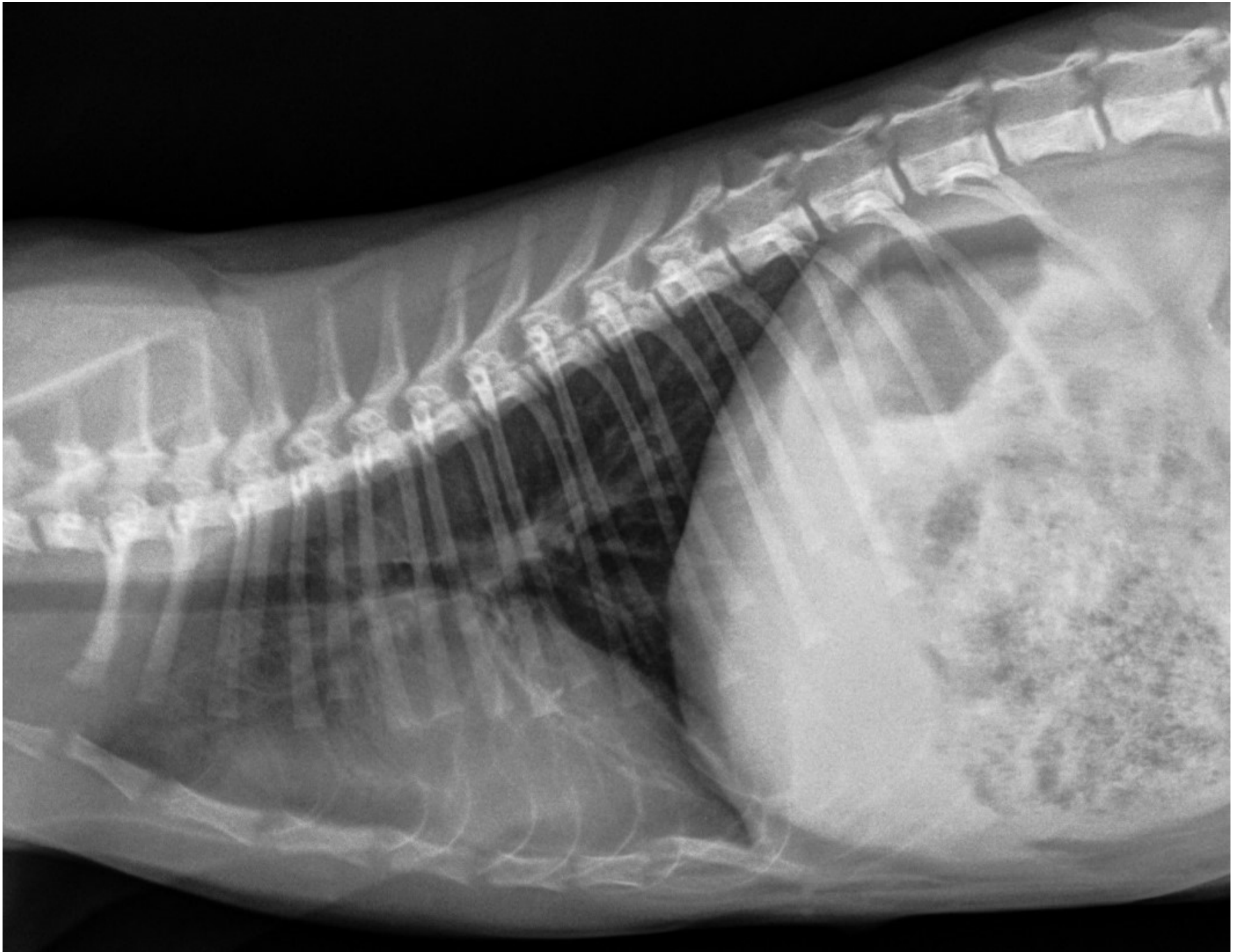

Supplementary Figure S3b. left lateral thoracic radiographs immediately after surgery.

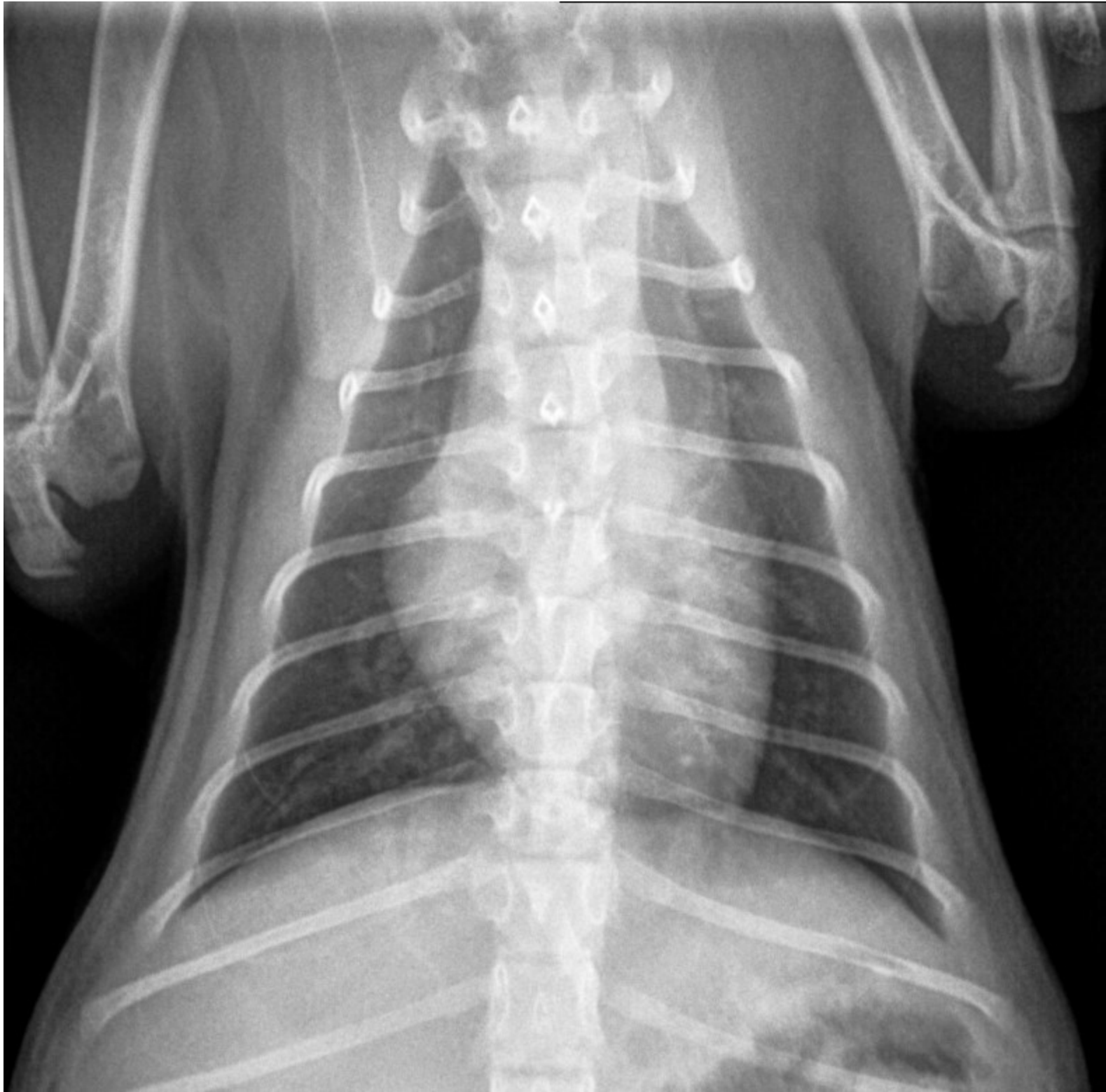

Supplementary Figure S3c. ventrodorsal, thoracic radiographs immediately after surgery. A mild pneumothorax is present increasing the distance from the sternum to the heart with the caudal lung lobes retracted away from the spine on the lateral radiographs and with the caudal lung lobes retracted away from the lateral body wall on the ventrodorsal radiograph.





Supplementary Figure S4a. Left lateral thoracic radiographs 7 weeks after surgery.



Supplementary Figure S4b. dorsoventral thoracic radiographs 7 weeks after surgery. A mild bilateral alveolar pattern is present cranially to the heart in all both radiographs.